

# Does a positioning rod or a patient-specific guide result in more natural femoral flexion in the concept of kinematically aligned total knee arthroplasty?

Max Ettinger<sup>1</sup> · Tilman Calliess<sup>1</sup> · Stephen M. Howell<sup>2</sup>

Received: 26 March 2016  
© Springer-Verlag Berlin Heidelberg 2016

## Abstract

**Purpose** Flexion of the femoral component in 5° increments downsizes the femoral component, decreases the proximal reach and surface area of the trochlea, delays the engagement of the patella during flexion, and is associated with a higher risk of patellar-femoral instability after kinematically aligned TKA. The present study evaluated flexion of the femoral component after use of two kinematic alignment instrumentation systems. We determined whether a distal cutting block attached to a positioning rod inserted perpendicular to the distal femoral joint line in the axial plane and 8–10 cm into the distal femur anterior and posterior to the distal cortex of the femur in the sagittal plane or a femoral patient-specific cutting guide sets the femoral component in more natural flexion.

**Methods** Flexion of the femoral component was measured with respect to the sagittal femoral anatomic axis of the distal diaphysis and the sagittal femoral axis on rotationally controlled long-leg lateral computer scanograms. Measurements were performed on 53 consecutive patients treated with a kinematically aligned TKA performed with a distal cutting block attached to a positioning rod, and 53 consecutive patients treated with a kinematically aligned

TKA performed with a femoral patient-specific cutting guide.

**Results** The average flexion and variability ( $\pm$ standard deviation) of the femoral component of patients treated with a positioning rod was  $1^\circ \pm 2^\circ$  and  $7^\circ \pm 4^\circ$  with respect to the anatomic and mechanical axes, respectively, which was 5° less than the average flexion of the femoral component of patients treated with a femoral patient-specific cutting guide of  $6^\circ \pm 4^\circ$  and  $12^\circ \pm 5^\circ$  ( $p = 0.0001$ ,  $p = 0.0001$ , respectively).

**Conclusions** Because a distal cutting block attached to a positioning rod sets the femoral component in 5° less flexion and with less variability than a femoral patient-specific cutting guide, we prefer this instrumentation system when performing kinematically aligned TKA to reduce the risk of patellar-femoral instability. Each surgeon should determine the repeatability of setting the flexion of the femoral component with this instrumentation system.

**Keywords** Knee arthroplasty · Internal and external rotation · Malrotation of components · Kinematic alignment · Oxford knee and WOMAC scores · Function

## Introduction

Patella-femoral complications are a common cause of patient dissatisfaction and a reason for revision after mechanically aligned total knee arthroplasty (TKA) [1, 14]. The settings of a femoral component designed for mechanical alignment are 3° to 5° of external rotation relative to the posterior condylar axis or the transepi-condylar axis in the axial plane, and 4° extension to 7° flexion relative to the mechanical axis of the femur in the sagittal plane [11, 15]. Occasionally, the femoral

✉ Max Ettinger  
Max@ettinger.info  
Tilman Calliess  
Tilman.calliess@ddh-gruppe.de  
Stephen M. Howell  
sebhowell@mac.com

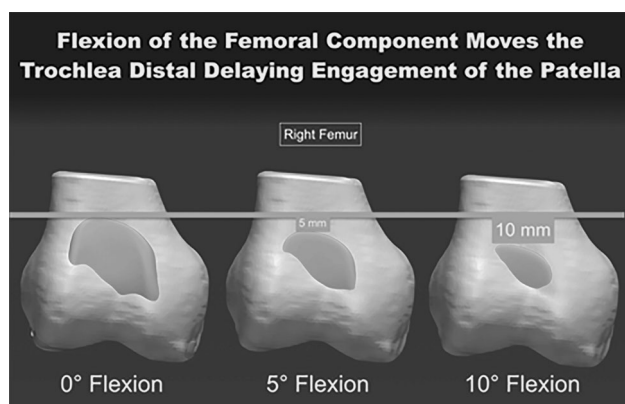
<sup>1</sup> Department of Orthopedic Surgery, Hannover Medical School, Hannover, Germany

<sup>2</sup> Department of Mechanical Engineering, University of California, Davis, Davis, CA 95616, USA

component is flexed and downsized when the anterior–posterior fit is acceptable and the medial–lateral fit is too wide [2, 16]. The potential concerns of flexion and downsizing of the femoral component are a decrease in the proximal reach and surface area of the trochlea, a delay the engagement of the patella during flexion, and an increased risk of patellar-femoral instability [2] (Fig. 1).

An alternative alignment method gaining interest is ‘kinematic alignment’, which restores the native distal and posterior femoral joint lines and proximal tibial joint lines [5, 6, 8]. A level one randomized trial reported the kinematic alignment technique provided better pain relief and restored better function and flexion than the mechanical alignment technique and a national multicenter study showed that patients treated with kinematically aligned TKA were three times more likely to report that their knee to felt ‘normal’ when compared to mechanically aligned TKA [3].

In the concept of kinematic alignment 4 of the 6 degrees of freedom to position the femoral component are set: varus/valgus alignment, distal/proximal position, rotation and anterior/posterior position. The mediolateral position is determined as the center of the distal femoral condyles and has little influence on the knee kinematics. The only parameter that is yet not clearly defined is the femoral component flexion. Again it is used to adapt the size of the femoral component for an optimal fit. In previous studies, it was described, that kinematic alignment sets the femoral component in 5° more flexion, 2° more valgus rotation, and 3° less external rotation than mechanical alignment, and yet has a similar 4.5% incidence of patella-related complications in the first two years [3]. The average flexion of the femoral component in patients treated with kinematic alignment that develop patella-femoral instability is 11°, which is 6° greater than a matched-cohort of patients without patella instability [12]. Hence, the aspired femoral

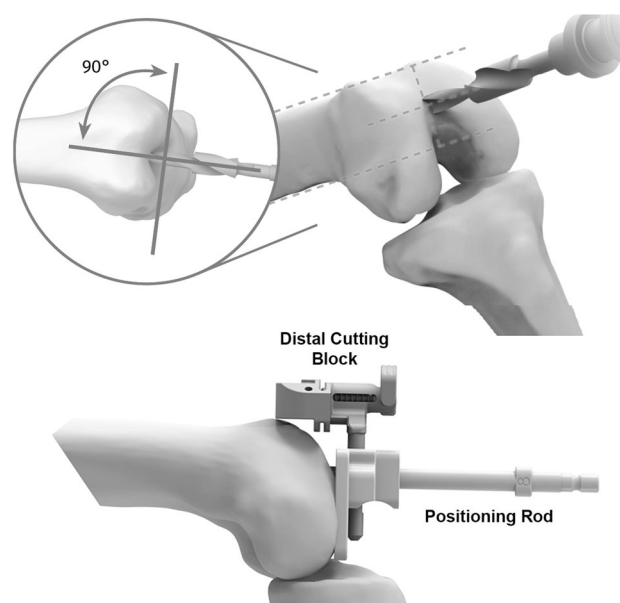


**Fig. 1** Schematic shows that flexing the femoral component 5° and 10° reduces the proximal reach of the trochlea 5 and 10 mm and reduces the size of the femoral component 1 and 2 increments [2]

component flexion with respect to the natural distal femur flexion is of clinical interest to reduce the risk of patella-femoral instability. Accordingly, we evaluated two kinematic alignment instrument systems that used either a distal cutting block attached to a positioning rod inserted perpendicular to the distal femoral joint line in the axial plane and 8–10 cm into the distal femur parallel to the anterior and posterior distal cortex of the femur in the sagittal plane or a femoral patient-specific cutting guide (Fig. 2). The present study determined which instrumentation sets the femoral component in less flexion compared to the natural distal femoral flexion.

## Methods and materials

A prospectively collected imaging database consisting of post-operative, long-leg anterior-posterior and lateral computer tomographic scanograms acquired during the hospital stay of approximately 3400 consecutive patients treated with kinematically aligned TKA was searched. The



**Fig. 2** Composite shows the instrumentation system for setting the flexion of the femoral component with use of a distal cutting block attached to a positioning rod inserted perpendicular to the distal femoral joint line in the axial plane and 8–10 cm into the distal femur anterior and posterior to the distal cortex of the femur in the sagittal plane. The starting point of the drill is midway between the top or anterior edge of the intercondylar notch and the anterior cortex of the femur. The orientation of the drill is perpendicular to the distal joint line of the femur in the axial plane and parallel to the anterior and posterior cortex of the distal femur in the sagittal plane. The positioning rod is inserted through the drill hole, 8–10 cm, into the distal femur. A more posterior starting point closer to the top of the intercondylar notch increases the risk of flexing the positioning rod and subsequently the femoral component with respect to the anterior and posterior cortex of the distal femur

indications for performing TKA were (1) disabling knee pain and functional loss unresolved with conservative nonoperative treatment modalities; (2) radiographic evidence of advanced arthritic change; and (3) all severities of varus, valgus, and flexion contracture deformities. Each TKA was imaged with a rotationally controlled long-leg scanogram in which the posterior condyles and lugs of the femoral component were superimposed in the lateral projection on the day of discharge<sup>5</sup>. Fifty-three consecutive patients treated with patient-specific instrumentation (OtisKnee, OtisMed, Inc, Alameda, CA) and with a cruciate retaining femoral component (Triathlon, Stryker, Mahwah NJ) from 7/1/2009 through 9/1/2009 were selected. Fifty-three consecutive patients treated with a distal cutting block attached to a positioning rod inserted perpendicular to the distal femoral joint line in the axial plane and 8–10 cm into the distal femur anterior and posterior to the distal cortex of the femur in the sagittal plane with a cruciate retaining femoral component (Persona, Zimmer Biomet, Warsaw, IN) from 4/1/2015 to 5/15/2015 were selected (Fig. 2). Because the imaging studies and clinical data were anonymized, their use was not subject to approval by our institutional review board. There were no differences in preoperative age, sex, body mass index, Oxford Knee Score, and Knee Society Function Score between treatment groups (Table 1). There were small differences in the average preoperative varus–valgus deformity, flexion, extension, and Knee Society Score between treatment groups.

Flexion of the femoral component was measured with respect to the femoral distal anatomic axis and the femoral mechanical axis in the sagittal plane. The sagittal femoral anatomic axis bisects a trapezoid best fit to the distal femoral diaphysis and corresponds to the portion of the


femur typically imaged by a lateral radiograph and a magnetic resonance image of the knee (Fig. 3) [7]. The sagittal femoral mechanical axis bisects a parallelogram that best fits the proximal and distal diaphysis of the femur at the junction of the metaphysis and corresponds to the portion of the femur typically imaged by a lateral radiograph of the femur (Fig. 4). The measurements of the flexion–extension of the femoral component with respect to the axes were performed with free, open-source, image analysis software (OsiriX, v.6.5.2 32bit, [www.osirix-viewer.com](http://www.osirix-viewer.com)) (Figs. 3, 4). The angle formed by the sagittal femoral anatomic axis and the sagittal femoral mechanical axis and a line drawn parallel to the lugs of the femoral component determined the flexion (+) and extension (–) of the femoral component.

### Statistical analysis

The reproducibility of the measurements of the flexion of the femoral component from the sagittal femoral anatomic axis and the sagittal femoral mechanical axis were determined by computing the intraclass correlation coefficient (ICC) with use of measurements made on ten randomly selected knees by two observers. The difference in the flexion–extension of the femoral component between the two instrumentation systems was determined with a Student's *T* test for measurements of flexion–extension of the femoral component measured with respect to the femoral anatomic and mechanical axes. The arithmetic mean, standard deviation (SD), and 95% confidence interval (CI) of the mean and standard deviation were computed for each measured quantity when appropriate (JMP, 10.02, <http://www.jmp.com>). Significance was  $p < 0.05$ .

**Table 1** Preoperative demographics and clinical characteristics

Preoperative demographics and clinical characteristics	Positioning rod ( $N = 53$ )	Patient-specific femoral cutting guide ( $N = 53$ )	<i>p</i> value
<b>Demographics</b>			
Age (years)	72 ± 9	69 ± 12	0.27, NS
Sex (male/female)	14/29	21/32	0.69, NS
Body mass index (kg/m <sup>2</sup> )	30 ± 4.8	29 ± 4.8	0.18, NS
<b>Preoperative motion and deformity</b>			
Extension (°)	13 ± 8.6	8 ± 3.5	0.02
Flexion (°)	110 ± 8.1	114 ± 13.5	0.01
Varus (+)/valgus (–) deformity (°)	5 ± 11.7	1 ± 10.2	0.01
<b>Preoperative function and mental scores</b>			
Oxford Score (48 is best, 0 is worst)	19 ± 8	20 ± 8	0.88, NS
Knee Society Score (100 is best, 0 is worst)	29 ± 147	39 ± 15.1	0.001
Knee Function Score (100 is best, 0 is worst)	46 ± 20.2	40 ± 23.3	0.18, NS



**Fig. 3** Illustration shows the methods for defining the sagittal femoral anatomic axis (SFAA) (blue line), which bisects a trapezoid best fit to the distal femoral diaphysis and corresponds to the portion of the femur typically imaged by an MRI and a lateral radiograph of

the knee. The angle between the sagittal femoral anatomic axis and a line drawn parallel to the lugs of the femoral component (black line) determined flexion (+)—extension (–) of the femoral component



**Fig. 4** Illustration shows the method for defining the whole sagittal femoral axis (sagittal femoral anatomical axis), which bisects a parallelogram that best fits the proximal and distal diaphysis of the femur at the junction with the metaphysis and corresponds to the

portion of the femur typically imaged by a lateral radiograph of the femur. The angle between the sagittal femoral mechanical axis and a line drawn parallel to the lugs of the femoral component (black line) determined flexion (+)—extension (–) of the femoral component

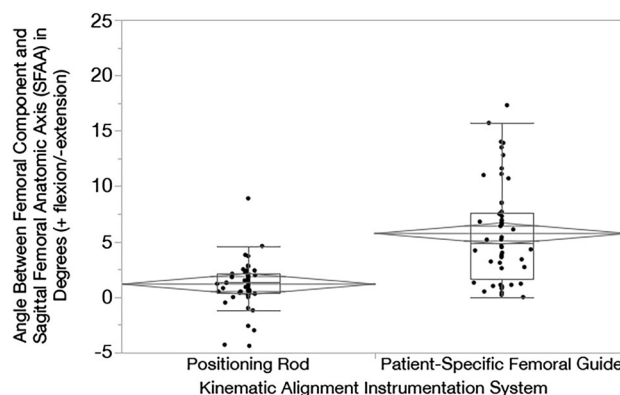
## Results

The ICC of 0.91 for the measurement of flexion of the femoral component from the sagittal femoral anatomic axis, and the ICC of 0.94 for the measurement of flexion of the femoral component from the sagittal femoral mechanical axis indicated high (first class) measurement reproducibility.

The difference between the natural sagittal distal femoral flexion with respect to the mechanical sagittal femoral flexion was  $7.4^\circ \pm 2.2^\circ$  in the cohort of the patient-specific cutting guide patients and  $6.9^\circ \pm 2.3^\circ$  in the cohort of positioning rod patients ( $p = 0.71$ ).

The average flexion of the femoral component with respect to the whole sagittal femoral anatomic axis of those patients treated with a positioning rod was  $1^\circ \pm 2^\circ$ , which was  $5^\circ$  less than the average flexion of the femoral component of patients treated with a femoral patient-specific cutting guide of  $6^\circ \pm 4^\circ$  ( $p = 0.0001$ , Fig. 5).

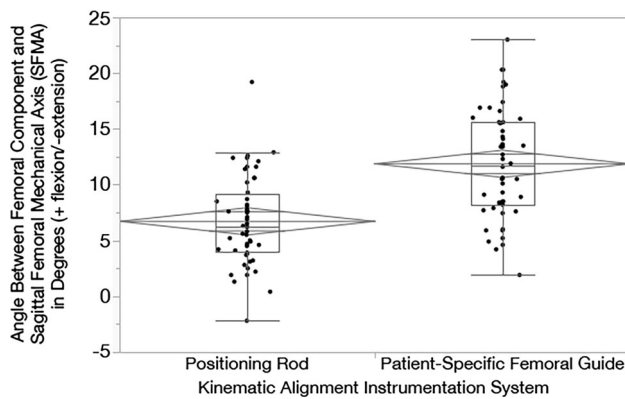
The average flexion of the femoral component with respect to the sagittal femoral mechanical axis of those patients treated with a positioning rod was  $7^\circ \pm 4^\circ$ , which was  $5^\circ$  less than the average flexion of the femoral component of patients treated with a femoral patient-specific cutting guide of  $12^\circ \pm 5^\circ$  ( $p = 0.0001$ , Fig. 6).



**Fig. 5** The graph displays the green transverse line and diamond that illustrates the mean and the 95% confidence interval of the mean, and the red outlier quartile box that shows the variability of the flexion–extension angle of the femoral component with respect to that of the sagittal femoral anatomic axis of the distal femur. The  $1^\circ \pm 2^\circ$  of flexion and variability for the use of the positioning rod instrumentation system was less than the  $6^\circ \pm 4^\circ$  of flexion of the femoral patient-specific cutting guide instrumentation system ( $p = 0.0001$ )

## Discussion

The most important findings of this study were that the instrumentation system that sets flexion of the femoral component with use of a distal cutting block attached to a



**Fig. 6** The graph displays the green transverse line and diamond that illustrates the mean and the 95% confidence interval of the mean, and the red outlier quartile box that shows the variability of the flexion–extension angle of the femoral component with respect to the of the sagittal femoral anatomical axis of the distal femur. The  $7^\circ \pm 4^\circ$  of flexion and variability for the use of the positioning rod instrumentation system was less than the  $12^\circ \pm 5^\circ$  of flexion of the femoral patient-specific cutting guide instrumentation system ( $p = 0.0001$ )

positioning rod inserted perpendicular to the distal femoral joint line in the axial plane and 8–10 cm into the distal femur anterior and posterior to the distal cortex of the femur in the sagittal plane set the femoral component in an average of  $5^\circ$  less flexion with respect to the sagittal femoral anatomic axis and the sagittal femoral mechanical axis than a femoral patient-specific cutting guide when performing kinematically aligned TKA. With the manual instrumentation the natural distal femoral flexion was met with a mean deviation by  $1^\circ$ , while the PSI were of this axis by  $6^\circ$  in average.

Two limitations should be discussed before interpreting the findings of our study. First, the results represent those of an experienced surgeon. Another kinematic alignment study of two surgeons that used a femoral patient-specific cutting guide reported  $10^\circ \pm 6^\circ$  of flexion of the femoral component with respect to the sagittal femoral anatomic axis, which is comparable to the  $7^\circ \pm 4^\circ$  reported by the present study [4]. Accordingly, inter-surgeon variability should be expected and intra-surgeon repeatability should be determined for the setting of the flexion of the femoral component. Second, although there were no differences in preoperative age, sex, body mass index, Oxford Knee Score, and Knee Society Function Score, there was a  $5^\circ$  difference in extension, a  $4^\circ$  difference in flexion, a  $4^\circ$  difference in varus-valgus deformity, and a ten point difference in the Knee Society Score between treatment groups. There is no reason to believe that these small differences caused the differences in the setting of the flexion of the femoral component between the positioning rod and the femoral patient-specific cutting guide.

The reproducibility of setting the flexion of the femoral component is clinically important and challenging as well. For an optimal patella tracking, an orientation of the femoral component flexion to the natural distal femoral flexion might have potential benefits for the patella tracking. A recent study focusing on patella instability after kinematically aligned TKA showed that patients with patella instability had greater flexion of the femoral component [13].

A mechanical alignment study reported that greater than  $3^\circ$  of flexion of the femoral component with respect to the sagittal femoral anatomic axis was associated with an increased risk of failure of the femoral component in a 16-year follow-up of study of 3048 TKAs treated with a low contact stress mobile-bearing rotation platform [9]. However, we could display a large physiological range of the natural flexion of the distal femur in our collective. This is not addressed specifically in the concept of mechanical alignment. Another mechanical alignment study reported that insertion of a 30 cm intramedullary alignment rod with a distal cutting block unreliably set flexion of the femoral component with respect to the sagittal femoral mechanical axis between  $0^\circ$  and  $3^\circ$  when checked intraoperatively with a pinless navigation system. The offered explanation for this unreliability was the surgeon's inability to foresee the extent of flexion of the femoral component with use of the intramedullary rod [10]. This again might be attributed to the large variability of the natural femoral flexion that has an impact on the intramedullary instrumentation. The inability to foresee the extent of flexion of the femoral component might also explain the  $10^\circ$  and  $5^\circ$  average flexion of the femoral component with respect to the sagittal femoral anatomic axis reported for kinematic alignment with a femoral patient-specific cutting guide and mechanical alignment with an intramedullary instrumentation system, respectively [4]. The special problem of the patient-specific cutting guide in this context is that the femoral flexion is determined on very short knee MRI scans. This is a potential source of the inaccuracy, because the femoral axis cannot be displayed reliable and certain intraoperative positioning errors occurred with the PSI blocks.

In contrast to this, the short intramedullary positioning rod inserted perpendicular to the distal femoral joint line meets the natural distal femoral flexion and sets the femoral component in significant less flexion compared to the cutting guides.

In summary, we prefer the short intramedullary positioning rod to restore the natural kinematic axes of the knee. Because of inter-surgeon variability, each surgeon should determine the repeatability of setting the flexion of the femoral component with this instrumentation system.



**Compliance with ethical standards**

**Conflict of interest** The authors have proprietary interests in the materials described in the article. The authors declare that they have no conflict of interest.

**Funding** There is no funding source.

**Ethical approval** This article does not contain any studies with human participants or animals performed by any of the authors.

**References**

1. Aglietti P, Buzzi R, Gaudenzi A (1988) Patellofemoral functional results and complications with the posterior stabilized total condylar knee prosthesis. *J Arthroplast* 3(1):17–25
2. Brar AS, Howell SM, Hull ML (2016) What are the bias, imprecision, and limits of agreement for finding the flexion-extension plane of the knee with five tibial reference lines? *Knee*. doi:10.1016/j.knee.2016.01.005
3. Dossett HG, Estrada NA, Swartz GJ, LeFevre GW, Kwasman BG (2014) A randomised controlled trial of kinematically and mechanically aligned total knee replacements: two-year clinical results. *Bone Joint J* 96-B(7):907–913. doi:10.1302/0301-620X.96B7.32812
4. Dossett HG, Swartz GJ, Estrada NA, LeFevre GW, Kwasman BG (2012) Kinematically versus mechanically aligned total knee arthroplasty. *Orthopedics* 35(2):e160–e169. doi:10.3928/01477447-20120123-04
5. Gu Y, Roth JD, Howell SM, Hull ML (2014) How frequently do four methods for mechanically aligning a total knee arthroplasty cause collateral ligament imbalance and change alignment from normal in white patients? *J Bone Joint Surg* 96(12):e101
6. Howell SM, Chen J, Hull ML (2013) Variability of the location of the tibial tubercle affects the rotational alignment of the tibial component in kinematically aligned total knee arthroplasty. *Knee Surg Sports Traumatol Arthrosc* 21(10):2288–2295. doi:10.1007/s00167-012-1987-5
7. Howell SM, Kuznik K, Hull ML, Siston RA (2010) Longitudinal shapes of the tibia and femur are unrelated and variable. *Clin Orthop Relat Res* 468(4):1142–1148. doi:10.1007/s11999-009-0984-6
8. Howell SM, Papadopoulos S, Kuznik K, Ghaly LR, Hull ML (2015) Does varus alignment adversely affect implant survival and function six years after kinematically aligned total knee arthroplasty? *Int Orthop* 39(11):2117–2124. doi:10.1007/s00264-015-2743-5
9. Kim YH, Park JW, Kim JS, Park SD (2014) The relationship between the survival of total knee arthroplasty and postoperative coronal, sagittal and rotational alignment of knee prosthesis. *Int Orthop* 38(2):379–385. doi:10.1007/s00264-013-2097-9
10. Maderbacher G, Schaumburger J, Baier C, Zeman F, Springorum HR, Birkenbach AM, Grifka J, Keshmiri A (2015) Appropriate sagittal femoral component alignment cannot be ensured by intramedullary alignment rods. *Knee Surg Sports Traumatol Arthrosc*. doi:10.1007/s00167-015-3541-8
11. Mahfouz MR, ElHak Abdel Fatah E, Bowers L, Scuderi G (2015) A new method for calculating femoral anterior cortex point location and its effect on component sizing and placement. *Clin Orthop Relat Res* 473(1):126–132. doi:10.1007/s11999-014-3930-1
12. Nedopil AJ, Howell SM, Hull ML (2016) Does malrotation of the tibial and femoral components compromise function in kinematically aligned total knee arthroplasty? *Orthop Clin N Am* 47(1):41–50. doi:10.1016/j.ocl.2015.08.006
13. Nedopil AJ, Howell SM, Hull ML (2016) What clinical characteristics and radiographic parameters are associated with patellofemoral instability after kinematically aligned total knee arthroplasty? *Int Orthop*. doi:10.1007/s00264-016-3287-z
14. Patel J, Ries MD, Bozic KJ (2008) Extensor mechanism complications after total knee arthroplasty. *Instr Course Lect* 57:283–294
15. Siston RA, Patel JJ, Goodman SB, Delp SL, Giori NJ (2005) The variability of femoral rotational alignment in total knee arthroplasty. *J Bone Jt Surg Am* 87(10):2276–2280. doi:10.2106/JBJS.D.02945
16. Tsukeoka T, Lee TH (2012) Sagittal flexion of the femoral component affects flexion gap and sizing in total knee arthroplasty. *J Arthroplast* 27(6):1094–1099. doi:10.1016/j.arth.2011.10.015